

“Research Reports”

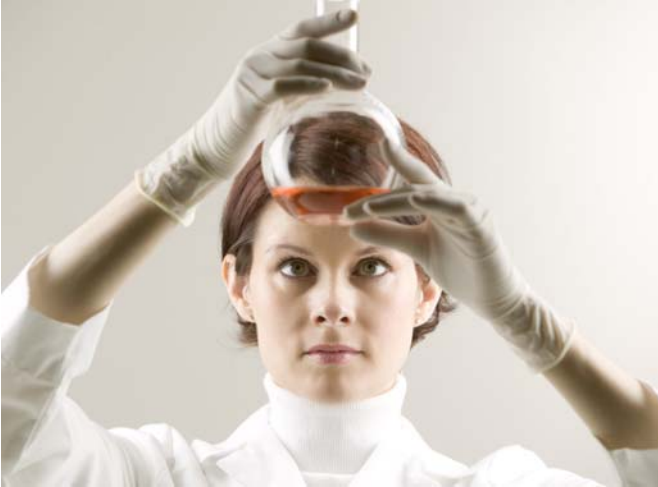

Important information on Dental Materials
and Sequential Removal

1-866-948-4638

Hal A Huggins, DDS, MS

Are Dental Materials Toxic?



The Truth:

- Many unexplained symptoms are related to dental mercury and root canals.
- Many diseases of unknown origin are related to dental mercury and root canals. Mercury fillings cause negative blood chemistry shifts.
- Typical mercury damage sites have now been identified
- There are other dental toxins.

Help is available!

“Research Reports”

Good news!

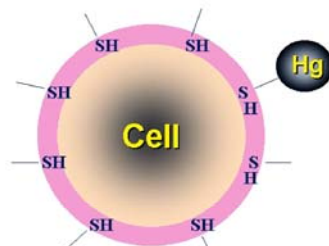
Autoimmune diseases can be stopped and many times reversed by a Dr. Huggins’ Protocol involving neutralizing reactions to dental materials.

What is an autoimmune disease? One in which your body’s immune white blood cells destroy your own body’s tissue cells. Examples of autoimmune nervous diseases are Multiple sclerosis, Amyotrophic lateral sclerosis, Alzheimer’s, Lupus, Leukemia, Diabetes and seizures. Examples of hormonal autoimmune problems are diabetes, Hashimoto’s thyroiditis and infertility.

“Hapten”

What creates the mistaken identity of cells as initiated from dental materials is the formation of a “Hapten”. A Hapten is a normal cell that acquires a hitchhiker that alters the cells “self” identification code.

Mercury Alters... Cell Membrane Structure / Function



Forms Hapten Immunologic “non-self”

Rothstein, A, Cell Membrane as Site of Action of Heavy Metals, Fed. Proc. 19: 1026-1038. 1959

In this picture, mercury, as from a common dental silver-mercury filling (about 50% mercury), is shown attaching itself to a normal cell. The new cell - called the Hapten – is mistaken by the immune system as being a foreign cell

Mercury from fillings can also create many common symptoms of “unknown” origin. Most commonly seen are symptoms of depression, anxiety, chronic fatigue, chronic headaches, digestive upsets and memory problems. These come from one or more of the three forms of mercury that can be created from the surface of “amalgam” fillings.

The three forms of mercury (called the 3 costumes of mercury) are:

- 1.) The vapor form - as it usually comes off from the filling (Chew, '91; Svare '81; Wataha '91)
- 2.) The ionic mercury form - also from the surface of the filling (Heintze '83)
- 3.) The methyl mercury form - formed by bacteria in the mouth and in the intestinal tract. (Compeau '84; Wood '74)

Examples of results of exposure to each form include:

Mercury vapor effecting the:

- Optic nerve (Ganser '85)
- Nasal sinus (Henricksson '98)
- Lungs (Sjostrand '70)
- Blood Brain Barrier (Nylander '87)

“Research Reports”

Ionic mercury effecting:

- Acute intracellular destruction (Friberg ‘86)
- Creation of “leaky membranes” (Friberg ‘86)
- Energy interference blocking Na-K pump (Aschner ‘90)
- Alters DNA (Canton and Costa ‘83)
- Creates neurotoxicity (Aschner ‘90)

Methyl Mercury effecting:

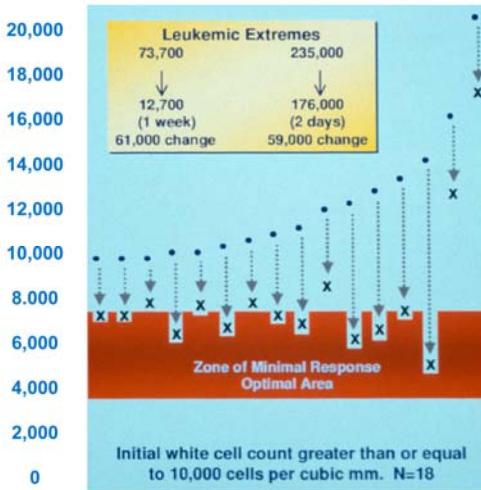
- Lipid soluble insidious poison (Lexmond ‘76)
- Endocrine disturbances (Friberg ‘86)
- Development of sensory neuropathy (Schionning ‘90)
- Plasmids convert ionic to methyl mercury (Konetzka ‘77)
- Muscle weakness (Rustam ‘75)
- Formation of haptens (Swartzendruber ‘88)

“Dental materials control a person’s immune system...”

Immune Dysfunction

As a result of treating thousands of patients, Dr. Huggins can demonstrate that dental materials control a person’s immune system. He showed examples of how high white blood cells can be reduced and low white blood cells increased by the same Protocol. (See figures I and II on page 5)

White Blood Cell Response To Sequential Removal of Silver-Mercury Fillings



Sequential Removal has the ability to balance the white blood cell count and increase the efficiency of your immune system.


(Right) Figure I

Demonstrates high white blood cell count dropping.

(Below) Figure II

Demonstrates low white blood cell count increasing.

Key: ● pre-treatment count
▲ direction after treatment
x post-treatment count



Further examples of immune dysfunction are shown by sophisticated studies of T- lymphocytes (a specific type of white blood cell) performed at the University of Colorado during his post doctoral masters studies. He showed the destruction of T-cells by placement of dental materials within a few days. Methods of recovery were also revealed. (See figures III, IV and V on page 6)

“Research Reports”

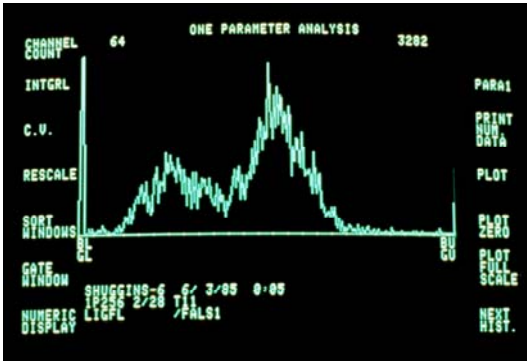


Figure III

Test results showing “normal” results for lymphocytes.

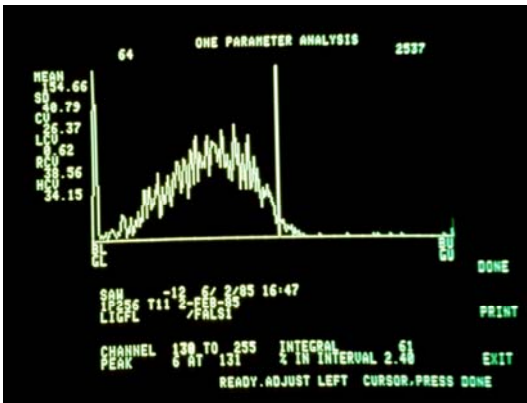


Figure IV

Results showing the destruction of T-lymphocytes within a few days.

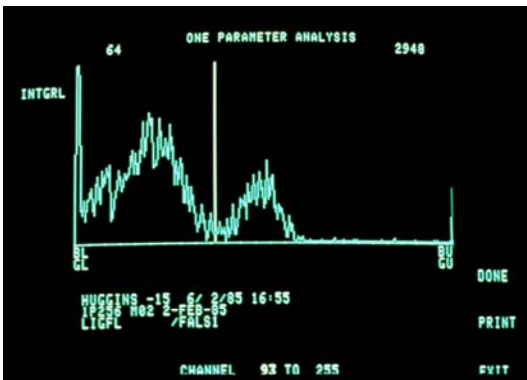


Figure V

Results showing the beginning of recovery.

Presence of abnormal proteins in spinal fluid in patients with Multiple Sclerosis that recovered to no abnormal proteins within 12 days utilizing the Protocol he discusses.

(See figure VI)

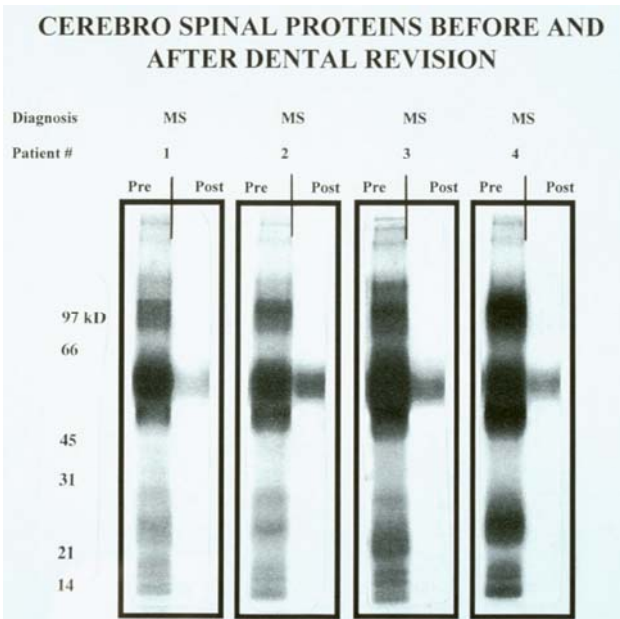


Figure VI
Demonstrates Cerebro Spinal Proteins of patients before and after dental revision.

Huggins has much more scientific data from thousands of patients that clearly demonstrates that certain dental materials (specifically mercury fillings and root canals) are not in the best interests of the health of unsuspecting, trusting patients.

“Research Reports”

The Saga Continues...

In 1996 Dr. Huggins and a few friends funded a study to bring several extremely ill British Gulf War Syndrome Vets to Colorado in the USA for treatment. This was an attempt to see if his Protocol would be effective against their conditions. His Protocol reversed the ravages of their conditions within a few days. Today all have recovered and are doing well.

***“Dr. Huggins’
Protocol
reversed their
conditions...”***

Obviously, this data is upsetting to the dental profession due to the massive potential for litigation. Huggins proposes that the dental profession and the public set aside legal issues and accusations and proceed toward the elimination of unnecessary diseases and symptoms.

A Word of Caution

Huggins cautions that the random removal of silver mercury fillings and root canal teeth can readily create new diseases. The Protocol he suggests involves using blood chemistries to guide health practitioner teams toward improving health and ridding the body of toxicity. It takes 3 days just to instruct the dentists in the methods of replacement of toxic substances with safer ones. Physicians need much more time to absorb the biochemical supportive and reconstructive methods for the injured immune system that must coordinate with the dental revisions.

“There are two ways to handle the situation”, to quote Huggins, “Fast, and Right.”

Sequential Removal

When we first discovered the tremendous advantage to removing fillings sequentially, we could see improvements in blood chemistry and symptoms very distinctly, but we had no clue as to *why* removing the negative fillings first produced improvements, and removing the positive fillings first produced a worsening of symptoms.

After 27 years of wondering, the answer suddenly appeared. I took a semester's course in Forensic Toxicology at the University of Colorado in 2005, and while studying brain reactions to prescription drugs, the “*Aha!*” occurred. All the bits and pieces of information leading to answering the question “**Why does sequential removal produce so much benefit?**” became clear.

I quickly wrote up the 20 pages of brain electro-biochemistry and incorporated it with endocrinology. The result was pretty thorough, but pretty complex to read. I have condensed the salient points into the following paragraphs. This appears to be the most important of multiple aspects of the Protocol in terms of what is lost if it is omitted.

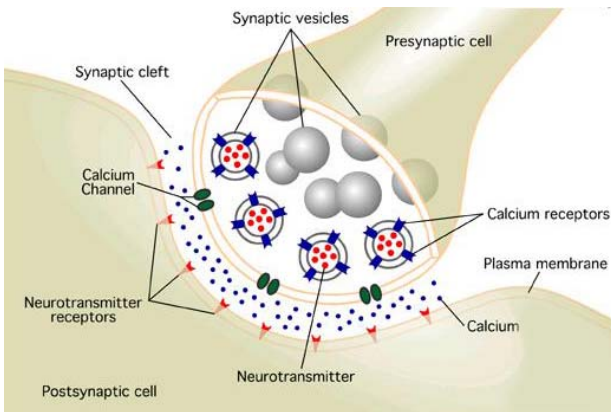


Figure VII

Diagram of a synapse.

“Research Reports”

In describing nerve impulse transmission, the most important element is the “synapse”, or space in between nerves. Nerves are not continuous, but are little snippets of nerve that convey electrical impulses along their fibers to a space that they have to jump to land on and to stimulate the next nerve fiber. A lot of complex bio-electro-chemical processes take place in that small space. There are chemicals called neurotransmitters that create chemicals at the end of one nerve. These chemicals jump into the space, and are directed to the other end of the chasm by calcium, magnesium, manganese, sodium, potassium and chloride all working in concert.

How it works...

Much of the action involves moving electrons (negatively charged) and protons (positively charged) within this space called the synaptic cleft. When everything is in balance, neurotransmitters stimulate the electrolytes to emit electrons that interact with protons and all the other electrolytes in that space resulting in the transfer of electrical energy from one nerve to the next.




Figure VII

A patient being tested with a meter designed to test electrical output from fillings to insure proper sequential removal.

Protons and Electrons

In touching a probe from an ammeter to a filling, the filling will generally register positive or negative. Sometimes it registers zero, which means that the filling has too much corrosion on it to allow electrical charges to escape. This does not mean that these fillings are safe. Actually, as a person eats, these corrosion products (several times more damaging than mercury vapor coming off the filling) are abraded off and mix with the food that is headed for the stomach, intestinal tract, and into the blood stream, with access to all parts of the body.

Here is my theory that explains the value of sequential removal.

When a filling registers “positive”, that means that *protons* are bombarding the ammeter’s probe, and, equal and opposite, *electrons* are rushing out the root end of the tooth. Directing our thoughts to the positive fillings, what is happening is that electrons are racing into the synapses of the brain. This influx of electrons creates an imbalance at the synapses, which causes the chemistry at the synapse to have to compensate, representing accommodation for survival.

Accommodation in this case involves bringing additional sodium ions into the synapse. Why? Because sodium can compensate for excess electrons and re-establish equilibrium in brain synaptic metabolism.

When the source of excess electrons is removed suddenly, as by the removal of a positively charged filling, compensating excess sodium no longer needed, but, at that moment, the synapse is over-saturated. Your nervous system has been compensating by leaning into the wind, so to speak, by providing excess sodium, and now it has to de-compensate because the electron challenge is no longer there.

“Research Reports”

How does this relate to people getting well or becoming more ill? The body is constantly balancing “degeneration versus regeneration”. This is a natural phenomena. We constantly get rid of aging cells, and replace them with new cells. Red blood cells live for 120 days, then are recycled out and replaced. White blood cells live only a week or two.

Degeneration—Regeneration.

Autonomic Nervous System

How does this happen? This decision is under the control of what is called the autonomic nervous system (ANS). The ANS decides when it is time to destroy and replace. It has two divisions. One for degeneration and one for regeneration. They are known as the sympathetic and para-sympathetic divisions. The sympathetic division is also known as the fight or flight division. When stimulated, these glands produce fight or die in trying hormones. To be specific, they are represented by the *thyroid hormone, adrenalin, anterior pituitary and testosterone*.

Counter to this action is the parasympathetic division of the ANS. These hormones include the *parathyroid hormone, insulin, posterior pituitary and estrogen*. Their specialty is in creating a calming and healing situation.

Should a dentist remove a positively charged dental filling first, the degeneration hormones are activated by the now-excess sodium in the synapse, creating an abnormal, hasty degeneration command.

These sympathetic hormones create a premature degeneration removal of tissues that are not really at the end of their life span - but there is no regeneration action to fill the vacancy. Thus, a new disease is created.

When fillings are removed sequentially, that is, with the negative fillings replaced first, the opposite scenarios takes place. As negative fillings are removed, a potassium efflux occurs at the synapse calling for an increase in parasympathetic hormones (parathyroid, insulin, posterior pituitary and estrogen). The result is to stimulate healing.

References

Chew, C. L., et al., Long-term dissolution of mercury from a non-mercury releasing amalgam. *Clin Rev Dent*, 13 (3): 5-7, 1991.

Svare, C. W., et al., The effect of dental amalgams on mercury levels in expired air. *J Dental Res* 50: Sept 1981.

Wataha, J. C. and Craig R. G., The release of elements of dental casting alloys into cell culture medium. *J Dent Research* 70: 1014-1018, 1991.

Compeau, G. and Bartha, R., Methylation and demethylation of mercury under controlled redox, pH and salinity conditions. *Applied & Environ Microbiol*, Vol 38, No 6, 1203-1207, 1984.

Wood, J., et al., Mechanisms for the Biomethylation of Metals and Metalloids. *Federation Proceedings, Biological and Pharmacological Effects of Metal Contaminants*, Vol 37, No 1, pp 16-21, January 1978.

Ganser, A. L. and Krischner, D. A., The interaction of mercurials with myelin, Comparison of in vitro and in vivo effects. *Neurotoxicology* 6 (1): 63-78, 1985.

Henriksson, J., et al., Uptake of inorganic mercury in the olfactory bulbs via olfactory pathways in rats. *Environ Research* 77(2): 130-140, 1998.

Sjostrand, J., Fast and slow components of axoplasmic transport in the hypoglossal and vagus nerves of the rabbit. *Cancer Research* 18: 461-467, 1970.

“Research Reports”

References Cont...

Nylander, M, Friberg, L. and Lind, V., Mercury concentrations in the human brain and kidneys in relation to exposure from dental amalgam fillings. *Swedish Dental J* 11: 179-187, 1987.

Friberg, Lars, Nordberg, Gunnar F. and Vouk, Velimir B. (eds.), *Handbook on the Toxicology of Metals*, Vol. I. Elsevier Science Publishing Co., New York, NY, 1986.

Aschner, M., et al., Mercury Neurotoxicity: Mechanisms of blood brain barrier transport. *Neuroscience and Bio-behavioral Reviews*, Vol. 14, 1990.

Canton, O. and Costa, M., Correlations of DNA strand breaks and their repair with cell survival, following acute exposure to mercury and X-rays. *Molecular Pharmacology* 24: 84-89, 1983.

Lexmond, T.M., et al., On the Methylation of Inorganic Mercury and the Decomposition of Organo-Mercury Compounds – A Review. *Neth. J Agric. Aci.* 24, 79-97, 1976.

Schionning, J. D., et al., Ultra-structural localization of mercury in rat dorsal root ganglia after exposure to mercury vapor. *Progress in Histo- and Cytochemistry*, Vol 23, 1990.

Konetzka, W., *Microbiology of metal transformation. Micro-organisms and Minerals*, 317-342, 1977

Rustam, H., et al., *Arch. Environ. Health*, 30: 190-195, 1975.

Swartzendruber, D. E., Adverse Immunomodulatory effects of heavy metals in dental materials. *Proceedings from the International Conference on Biocompatibility of Materials*, 1988.

Hal A. Huggins DDS, MS



Dr. Hal A Huggins has been a cutting edge researcher in dental toxicity since 1973. Why cutting edge? Because he follows changes in immune reactivity relative to sensitivities to dental toxins—and reports them. He uses blood chemistry evaluations to determine what dental

materials and supplements are “naughty” and which are “nice”. This upsets a great financial institution that has had a low key white knight reputation for over 100 years. What are the consequences of his observations? Exposure of massive liability. Resulting in lie-ability. Greater liability than Enron. Greater than the tobacco fiasco. Who does it affect? Most everyone. Probably you.

He is presenting the observations of the last 37 of his 43 years of practice. These comments are connections he has seen between dental materials and incurable diseases. He has lectured professionally 1400 days in 46 of the U.S. states and 13 other countries. He has authored several books, written over 50 articles, and given over 1000 radio/ TV interviews.

He received a post-doc Master’s at the University of Colorado with emphasis on immunology/toxicology. He successfully pioneered treatments for autoimmune diseases due to dental toxins and has personally treated over 2500 toxic patients.

Which dental materials are implicated? Mercury, nickel, beryllium, copper, and toxins formed in dead or root canal teeth as well as in cavitations.



Balanced Chemistry

For Better Health

Creating Positive Health Alternatives

Important Information on Dental Materials and Sequential Removal

Huggins Applied Healing
4685 Centennial Blvd
Colorado Springs, CO 80919

1-866-948-4638

HugginsAppliedHealing.com

info@drhuggins.com



Visit our website!

www.DrHuggins.com

There is Hope!

Many people have been told their health problems are all in their head because their symptoms or diseases have no medically known cause or treatment. Dr. Huggins has discovered that dental toxicity due to mercury in amalgam fillings is the cause of many of these unexplained diseases and symptoms. Other standard dental practices such as root canals have also been shown to contribute to many health issues that the medical community has no explanation for.



Call us toll-free today!

1-866-948-4638